

# Reduced mandibular cast splints—an alternative in Herbst therapy? A prospective multicentre study

Julia von Bremen, Hans Panherz and Sabine Ruf

Department of Orthodontics, University of Giessen, Germany

**SUMMARY** The aim of this study was to analyse anchorage loss with reduced, in comparison with total mandibular cast splints during Herbst treatment. Lateral head films of 32 Class II division 1 patients (15 females, 17 males) aged 13.0 years with reduced mandibular cast splints (RMS: second premolar to second premolar) and of 34 Class II division 1 patients (19 females, 15 males) aged 13.9 years with total mandibular cast splints (TMS: molar to molar) were analysed before (T1) and directly after (T2) Herbst treatment. Anchorage loss was assessed considering mandibular incisor proclination, changes of lower incisor edge position, and changes of occlusal plane inclination. To assess possible group differences, Student's *t*-tests were applied.

The lower incisors proclined more in the RMS (11.8 degrees) than in the TMS (9.3 degrees) group. However, the amount of incisal edge advancement was less in the RMS (2.9 mm) than in the TMS (3.7 mm) group. The occlusal plane tilted insignificantly less in the RMS (5.7 degrees) than in the TMS (6.3 degrees) group. Reduced and total mandibular casted splint anchorage seemed to be similarly effective. Anchorage loss, measured by mandibular incisor proclination, was greater in the reduced anchorage group, whereas measured by lower incisor edge advancement, it was larger in the total anchorage group. Therefore, RMS can be recommended for Herbst treatment since they are less expensive than total splints.

## Introduction

Due to an increased demand for efficient orthodontic treatment, the Herbst appliance has become increasingly popular for the treatment of Class II malocclusions. Nowadays, it is the most commonly used appliance for Class II treatment in the United States (McNamara and Brundon, 2001; Keim *et al.*, 2002). When the original appliance was first introduced (Herbst, 1910), anchorage in the lower jaw consisted of only two bands on the lower canines. Herbst was strongly criticized (Schwarz, 1934) since it was believed that too great a load was exerted on the teeth, thus leading to periodontal problems. These arguments, although never proven correct, caused the Herbst appliance to be almost forgotten, until rediscovered in 1977 (Panherz, 1979). Panherz tried to reduce the load on the anchorage teeth by replacing the bands by cast splints, extending from the canines to the first molars (Figure 1a). These total mandibular cast splints (TMS) have been the appliances used for the past 10 years in the orthodontic department of the University of Giessen.

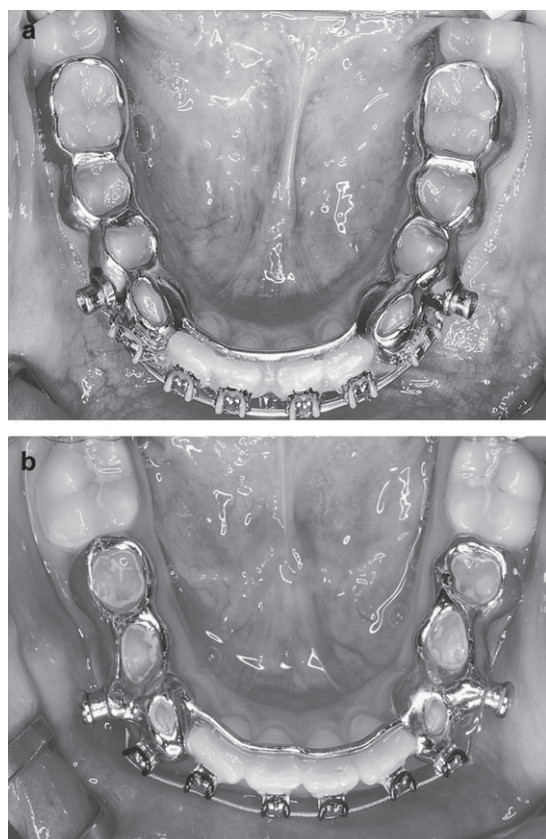
The mandibular dental changes occurring during Herbst treatment are due to anchorage loss as a result of the mesially directed forces exerted on the mandibular teeth by the telescope mechanism. Especially proclination and/or protrusion of the lower incisors are generally an undesirable side-effect. Although many different Herbst designs testing a variety of different anchorage forms have been used, none has been able to prevent or consistently reduce mandibular

incisor proclination (Panherz and Hansen, 1988; Hansen, 1992; Weschler and Panherz, 2005).

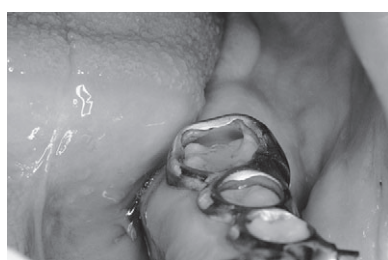Although the frequency of complications has been shown to be similar for banded and cast splint Herbst designs (Hägg *et al.*, 2002; Sanden and Panherz, 2004), cast splints have been shown to be superior to banded designs because of savings in chair and laboratory time (Hägg *et al.*, 2002). However, as a result of tilting of the lower occlusal plane occurring during Herbst therapy (Panherz, 1982; Müller, 2000), a complication during treatment is a partial dislodgement of the lower splints from the posterior teeth (Figure 2). This leads to spacing between the lower molars and the splints in which plaque and food debris gathers, since they are difficult to clean for the patient. As the occlusal plane is indirectly levelled during Herbst therapy, recementation of these partial dislodgements is not possible.

Since anterior movement of the mandibular teeth could not be prevented, regardless of the anchorage system used, it was assumed that reduced mandibular cast splints (second premolar to second premolar; Figure 1b) might be as effective as extended splints (molar to molar), less expensive, and thus more economical.

The aim of this study was to answer the question: is there a difference in anchorage loss between subjects treated with reduced [premolar to premolar: reduced mandibular cast splints (RMS)] and those treated with TMS (molar to molar)? The null hypothesis was that there is no difference



**Figure 1** Mandibular anchorage forms used in Herbst treatment. (a) Total mandibular cast splint from first molars to canines connected by a lingual bar. (b) Reduced mandibular cast splints from second premolars to canines connected by a lingual bar.



**Figure 2** Partial dislodgement of a lower cast splint from the molar.

in anchorage loss between RMS and TMS during Herbst therapy.

### Subjects and methods

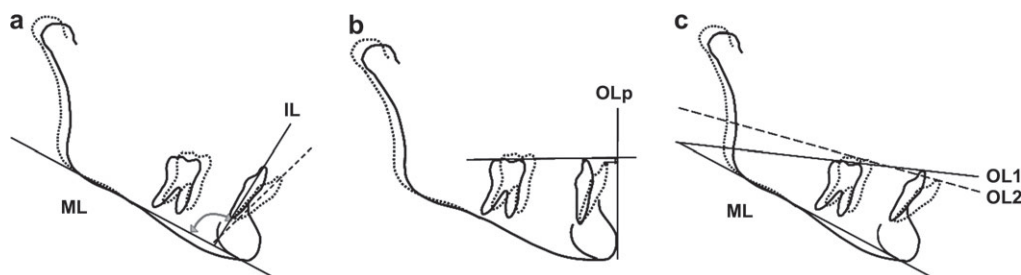
All Class II division 1 subjects from the orthodontic departments of the Universities of Giessen, Germany and Berne, Switzerland, in which Herbst treatment was started after February 2003, were consecutively enrolled in this prospective study. All were in the permanent dentition, had a uni- or bilateral Class II molar relationship of half or more cusp width, an overjet of at least 5 mm before treatment,

and were 'jumped' to an incisal edge-to-edge position with the Herbst appliance. Exclusion criteria were syndromes and agenesis or premature loss of permanent teeth. Instead of the TMS used before February 2003, the subjects were treated with RMS. All patients agreed to be treated with RMS and all completed Herbst therapy. Those subjects who had their Herbst appliance removed before November 2004 were considered. Thirty-two subjects (15 females, 17 males) with an average age of 13.0 years fulfilled these criteria.

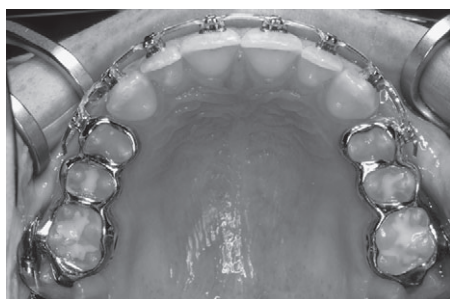
Lateral head films in habitual occlusion from before orthodontic therapy (T1) and directly after Herbst treatment (T2) were analysed. For assessment of anchorage loss, the amount of lower incisor proclination (IL/ML) and the incisal edge advancement (i-OLp) was measured. In addition, the amount of occlusal plane inclination change was analysed (Figure 3). While incisor proclination and occlusal plane inclination were measured separately on pre- and post-Herbst radiographs, the post-treatment incisal edge advancement was determined after transferring the occlusal line perpendicular (OLp) from the first lateral head film to the second by superimposition of the radiographs on stable bone structures of the mandible, namely the symphysis and the lower mandibular border (Björk and Skieller, 1972). All linear and angular measurements were taken to the nearest 0.5 mm and 0.5 degrees, respectively. No correction for linear enlargement, which was approximately 7 per cent for both cephalostats (Giessen and Berne), was undertaken. All measurements were performed twice with at least a 2-week interval between the duplicate registrations. In the final evaluation, the mean value of the two registrations was used.

These first 32 patients treated with RMS were compared with the first 34 consecutive Class II division 1 patients (19 females, 15 males) who had been treated with TMS at the University of Giessen starting in April 1990. These subjects were derived from the patient material of Weschler and Pancherz (2005). The inclusion criteria were the same as for the RMS group; all were in the permanent dentition, had a uni- or bilateral Class II molar relationship of half or more cusp width, an overjet of at least 5 mm before treatment, and were jumped to an incisal edge-to-edge position upon insertion of the Herbst appliance. All patients completed Herbst treatment. Their average age at T1 was 13.9 years. Thus, concerning the pre-treatment severity of the malocclusion and the average age, the TMS subjects were comparable with the RMS subjects. The appliances used in the maxilla were identical for both groups and consisted of two cast splints extended from the first premolar on each side to the first molar (Figure 4).

Statistical analysis was performed by applying Student's *t*-tests to assess possible group differences. Statistical significance was determined at the 0.1, 1, and 5 per cent levels of confidence.



**Figure 3** Measurement of (a) mandibular incisor proclination, (b) mandibular incisal edge advancement, and (c) occlusal plane inclination.



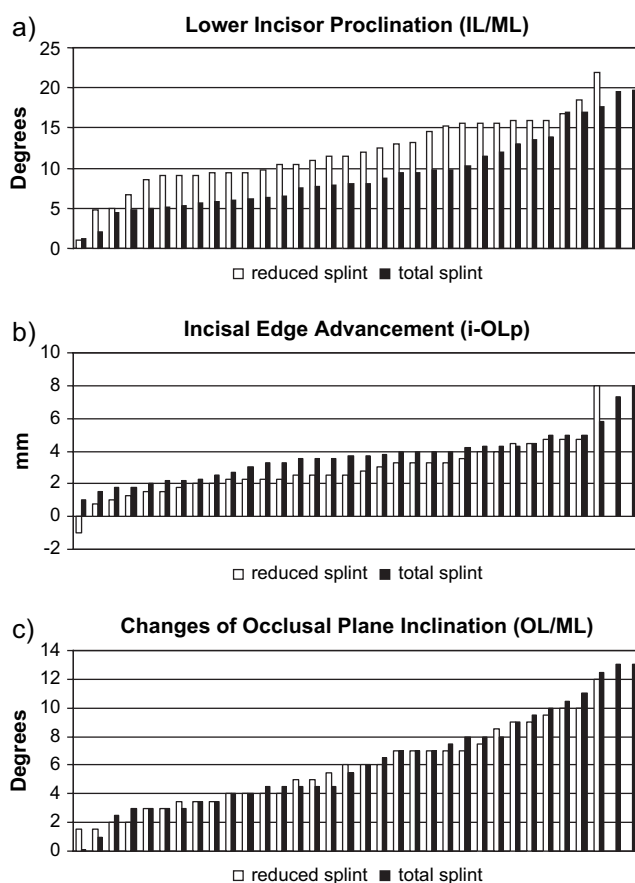
**Figure 4** Maxillary cast splints used for both the reduced and total mandibular splint appliances.

## Results

In both groups, active treatment duration (T1–T2) was comparable, being 7.2 months for the RMS and 7.0 months for the TMS group. At appliance removal, all subjects had been successfully treated to a bilaterally overcorrected Class I molar relationship as well as an incisal edge-to-edge position or anterior crossbite. Although the patients were treated by different clinicians (postgraduate students, senior residents or department heads), they were pooled since it was assumed that the qualification of the clinician had no influence on the amount of anchorage loss during the Herbst phase. Furthermore, there were no operator differences between the groups. Except for a slightly more protrusive incisor position in RMS males compared with the RMS females at T1 and T2, no gender differences were found between the groups. In addition, since the treatment changes were comparable between the gender groups, male and female subjects were pooled within their respective appliance groups.

### Mandibular incisor proclination

At T1, the RMS subjects had an average IL/ML angle of 96.4 degrees, which at T2 had increased by 11.8 to 108.2 degrees. The amount of proclination ranged from 1.0 to 22.0 degrees. The TMS subjects had an average IL/ML angle of 100.8 degrees at T1, which had increased by 9.3 to 110.1 degrees at T2. The amount of proclination ranged from 1.2 to 19.7 degrees in the TMS group (Figure 5a).



**Figure 5** Individual treatment changes in increasing order of (a) lower incisor proclination (IL/ML), (b) lower incisal edge advancement (i-OLp), and (c) occlusal plane inclination during Herbst therapy of subjects treated with reduced ( $n = 32$ ) and total ( $n = 34$ ) mandibular cast splints.

Comparing the groups, it was found that the RMS subjects had a significantly ( $P < 0.05$ ) less proclined incisor position at T1, but that their incisors proclined more (2.5 degrees;  $P < 0.05$ ) during treatment (Table 1).

### Mandibular incisor edge position

At T1, the lower incisors in the RMS subjects were 2.4 mm anterior to OLp and advanced another 2.9 mm during treatment. The amount of incisal edge advancement ranged

**Table 1** Group differences of the variables IL/ML, i-LOp, and OL/ML between the reduced and total mandibular cast splint groups before (T1) and after (T2) Herbst treatment.

Variables	Reduced splint (n=32)		Total splint (n=34)		Group differences  P
	Mean	SD	Mean	SD	
IL/ML (T1)	96.35	7.91	100.80	5.86	<0.05
IL/ML (T2)	108.18	9.56	110.08	4.90	n.s
IL/ML (T2–T1)	11.83	4.35	9.28	4.71	<0.05
i-OLP (T1)	2.44	3.65	1.79	3.06	n.s
i-OLP (T2)	5.29	4.05	5.46	2.94	n.s
i-OLP (T2–T1)	2.85	1.61	3.68	1.51	<0.05
OL/ML (T1)	20.28	1.53	20.28	4.93	n.s
OL/ML (T2)	14.55	3.69	14.04	3.73	n.s
OL/ML (T1–T2)	5.73	2.76	6.24	3.39	n.s

IL/ML, lower incisor proclination; i-OLP, lower incisal edge advancement; SD, standard deviation; n.s., not significant.

from –1 to +8 mm. The lower incisors of the TMS subjects were closer to OLp before treatment (1.8 mm) but advanced more (3.7 mm) during therapy. The incisal edge advancement in the TMS group ranged from +1 to +8 mm (Figure 5b). The group comparison at T1 showed no statistically significant difference between the two groups. Concerning the greater incisal edge advancement in the TMS group during Herbst treatment, a slight statistical significance was observed ( $P < 0.05$ ) (Table 1).

### Occlusal plane inclination

The OL/ML angle was identical (20.3 degrees) in both groups at T1. Throughout Herbst treatment, the occlusal plane tilted slightly less (5.7 degrees) in the reduced than in the total anchorage group (6.3 degrees; Figure 5c). This was, however, not statistically significant (Table 1).

### Discussion

Pancherz and Hägg (1985) showed that the lower incisors of patients treated after the pubertal growth peak generally tended to procline more than those of younger patients. In the present study, the skeletal maturity of the subjects was not considered, but since the average age of both groups was comparable (13.0 years for reduced anchorage, 13.9 years for total anchorage), it can be assumed that this was not the decisive factor for the group differences. It might be speculated, however, that the higher average age of the TMS subjects (9 months) lead to more dental than skeletal changes. This could possibly explain the greater incisal edge advancement in the TMS than in the RMS group. The anchorage loss as measured by lower incisor proclination, however, gave contradictory results, being less for the older (TMS) than for the younger subjects (RMS).

Those patients treated with RMS anchorage had a less proclined but more protruded lower incisor position than the TMS group at T1. During Herbst treatment, they proclined more (+2.5 degrees;  $P < 0.05$ ) but protruded less (–0.8 mm;  $P < 0.05$ ) than in the TMS group. These findings are contradictory as it would be expected that a larger proclination would result in increased incisal edge protrusion. This contradiction is difficult to explain. The only possible explanation would be that part of the inclination changes in the RMS group was due to lingual root torque. However, no active root torque was applied to the incisors. Theoretically, it also appears possible that the whole lower segment (5–5) of the RMS anchorage torques as a unit through the lever of the telescope mechanism. Despite the group difference, its clinical significance and predictive power must be questioned because of the very large inter-individual variation in both groups, with individual differences up to 21 degrees for proclination.

Concerning the changes in occlusal plane inclination, it was observed that the occlusal plane tilted less in the RMS than in the TMS group. This can be explained by the definition of the occlusal plane, which was defined as a line connecting the mesial cusp of the lower first molar to the lower incisal edge. Both groups showed a clockwise rotation of the occlusal plane, but since the first molar was not included in the cast splints of the reduced anchorage group, it consequently was not extruded actively as was the molar of the total anchorage group.

Another sign of anchorage loss is the advancement of the mandibular molars, which was also evaluated for TMS by Weschler and Pancherz (2005). In the present study, this was not considered since the reduced splints do not reach the molars. Thus, no active movement of the lower molars due to the appliance can be expected.

Both groups contained patients with a significant loss of anchorage, but also those with hardly any anchorage loss at all. If there had been an important difference between RMS or TMS, it can be assumed that the above findings would have been more obvious in one direction or the other. Concerning the amount of complications during Herbst treatment, RMS can also be recommended as they were not dislodged more often than TMS, but, on the contrary, were superior to TMS concerning the frequency of complications per patient (unpublished results).

### Conclusion

Based on the findings of this study, it can be concluded that RMS are an alternative to TMS anchorage in Herbst treatment since the amount of anchorage loss does not differ significantly between both groups. Thus, the null hypothesis could be confirmed. Since, however, reduced splints are more economical than total splints, they can be recommended for Herbst therapy.

**Address for correspondence**

Dr Julia von Bremen  
 Department of Orthodontics  
 University of Giessen  
 Schlangenzahl 14  
 35392 Giessen  
 Germany  
 E-mail: Julia.v.Bremen@dentist.med.uni-giessen.de

**References**

- Björk A, Skieller V 1972 Facial development and tooth eruption: an implant study at the age of puberty. *American Journal of Orthodontics* 62: 339–383
- Hägg U, Tse E L, Rabie A B, Robinson W 2002 A comparison of splinted and banded Herbst appliances: treatment changes and complications. *Australian Orthodontic Journal* 18: 76–81
- Hansen K 1992 Post-treatment effects of the Herbst appliance. A radiographic, clinical and biometric investigation. *Swedish Dental Journal. Supplement* 88: 1–49
- Herbst E 1910 Verhandlungen des V. Internationalen Zahnärztlichen Kongresses, pp. 351–353.
- Keim R G, Gottlieb E L, Nelson A H, Vogels D S 2002 JCO study of orthodontic diagnosis and treatment procedures. Part 1. Results and trends. *Journal of Clinical Orthodontics* 36: 553–568
- McNamara J A, Brundon W 2001 *Orthodontics and dentofacial orthopedics*. Needham Press Inc., Michigan, p. 289
- Müller A 2000 Das Verhalten der Okklusionsebene bei kieferorthopädischer Therapie mittels Aktivator, Tip-Edge-oder Herbst-Apparatur. Thesis, University of Giessen, Germany
- Pancherz H 1979 Treatment of Class II malocclusions by jumping the bite with the Herbst appliance. A cephalometric investigation. *American Journal of Orthodontics* 76: 423–442
- Pancherz H 1982 Vertical dentofacial changes during Herbst appliance treatment. A cephalometric investigation. *Swedish Dental Journal. Supplement* 15: 189–196
- Pancherz H, Hansen K 1988 Mandibular anchorage in Herbst treatment. *European Journal of Orthodontics* 10: 149–164
- Pancherz H, Hägg U 1985 Dentofacial orthopedics in relation to somatic maturation. An analysis of 70 consecutive cases treated with the Herbst appliance. *American Journal of Orthodontics and Dentofacial Orthopedics* 88: 273–287
- Sanden E, Pancherz H 2004 Complications during Herbst appliance treatment. *Journal of Clinical Orthodontics* 38: 130–133
- Schwarz A M 1934 Erfahrungen mit dem Herbstschen Scharnier zur Behandlung des Distalbisses. *Zahnärztliche Rundschau* 43: 91–100
- Weschler D, Pancherz H 2005 Efficiency of three mandibular anchorage forms in Herbst treatment: a cephalometric investigation. *Angle Orthodontist* 75: 23–27